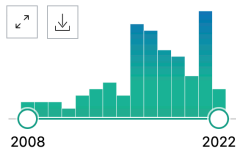


MY NCBI FILTERS

83 results

RESULTS BY YEAR



TEXT AVAILABILITY

- Abstract
- Free full text
- Full text

ARTICLE ATTRIBUTE

- Associated data

1094/

1 Positive signs on physical examination are not always indications for endotracheal tube intubation in patients with facial burn.

Cite Huang RY, Chen SJ, **Hsiao YC**, Kuo LW, Liao CH, Hsieh CH, Bajani F, Fu CY. BMC Emerg Med. 2022 Mar 8;22(1):36. doi: 10.1186/s12873-022-00594-9. Share PMID: 35260094

2 Simultaneous Paramedian Pedicle Forehead and Free Medial Sural Artery Perforator Flap Reconstruction of a Composite Nasal Defect: A Case Report.

Cite Liao KH, Yen CI, Chang CS, **Hsiao YC**. Ann Plast Surg. 2022 Mar 1;88(1s Suppl 1):S106-S109. doi: 10.1097/SAP.0000000000003131. Share PMID: 35225856

3 "Nasal lining rotation flap with triangular fossa composite graft, an effective method for managing the multiply-revised Asian short nose".

Cite Shyu VB, Yen CI, Chang FC, **Hsiao YC**. J Plast Reconstr Aesthet Surg. 2021 Nov 14:S1748-6815(21)00559-3. doi: 10.1016/j.bjps.2021.11.015. Online ahead of print. Share