

The Folded Ulnar Forearm Flap for Nasal Reconstruction

Yen-Chang Hsiao, M.D.

Jung-Ju Huang, M.D.

Jonathan A. Zelken, M.D.

Chih-Wei Wu, M.D.

Chun-Shin Chang, M.D.

Mohamed Abdelrahman,

M.D.

Georgios Kolios, M.D.,

M.B.A.

Taipei, Taiwan; Khartoum, Sudan; and
Hamburg, Germany



Background: Many strategies exist to reconstruct composite nasal defects, but free flaps are necessary for extensive defects. The workhorse radial forearm flap is hair-bearing and donor-site cosmesis is unfavorable. The ulnar forearm flap is overlooked despite important aesthetic benefits. The authors describe their experience with the ulnar forearm flap, with a novel folding technique in staged nasal reconstruction.

Methods: Between December of 2010 and April of 2015, 10 nasal reconstructions in five men and five women were performed. Average patient age was 47.6 years (range, 31 to 76 years). The ulnar forearm flap was designed as a narrow contiguous flap along the ulnar vascular axis. Inset began with the nasal floor; the flap was then tubularized twice to create nasal passages before it was folded on itself for coverage. Caudal edges were sewn together to create alae and a columella. Follow-up time, complications, number of operations, and reconstructive duration were documented.

Results: Average follow-up was 25.2 months (range, 18 to 44 months). Patients had satisfactory aesthetic and functional outcomes after 6.4 operations (range, five to eight) over 11.1 months (range, 8 to 18 months). Partial necrosis of the alar lining in one case was salvaged with the covering flap. Two cases of chondritis were managed with conservative débridement and antibiotics. One case of severe chondritis necessitated removal and de novo reconstruction.

Conclusions: The ulnar forearm flap is safe and reliable in nasal reconstruction, with superior donor-site cosmesis. The tubular folding method creates a vascular envelope amenable to same-stage framework construction. With thoughtful planning and sufficient refinement, excellent aesthetic and functional results are achievable. (*Plast. Reconstr. Surg.* 137: 630, 2016.)

CLINICAL QUESTION/LEVEL OF EVIDENCE: Therapeutic, V.

Reconstruction of full-thickness nasal defects such as the one shown in Figure 1 can be a formidable challenge. Locoregional options such as the forehead flap carry a long track record of success, and numerous methods for composite reconstruction exist. However, locoregional flaps alone may not be adequate to accommodate extensive composite defects; free tissue transfer is the only option.¹⁻³ Lining is addressed first in composite nasal reconstruction. Methods for nasal lining replacement

are varied,¹⁻⁵ but the free radial forearm flap is commonly used because of its ease of harvest, reliable blood supply, and pliability.^{1,2} A major disadvantage is donor-site appearance. The ulnar forearm flap offers nearly identical benefits and favorable donor-site appearance. We present a novel method for lining replacement in composite nasal reconstruction.

Disclosure: The authors have no financial interest to declare in relation to the content of this article.

Supplemental digital content is available for this article. Direct URL citations appear in the text; simply type the URL address into any Web browser to access this content. Clickable links to the material are provided in the HTML text of this article on the *Journal's* Web site (www.PRSJournal.com).

From the Department of Plastic and Reconstructive Surgery, Chang Gung Memorial Hospital, College of Medicine, Chang Gung University; the Department of Surgery, Faculty of Medicine, University of Khartoum; and the Department of Plastic and Reconstructive Surgery, Agaplesion Diakonie Klinikum.

Received for publication May 1, 2015; accepted September 16, 2015.

Copyright © 2016 by the American Society of Plastic Surgeons

DOI: 10.1097/01.prs.0000475783.91456.3f

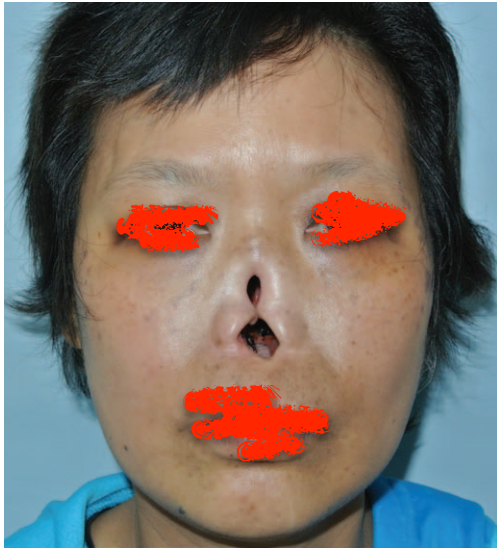

Fig. 1. A 48-year-old woman with lymphoma was treated with chemotherapy and radiation therapy that led to a nearly total secondary nasal defect. Reconstruction began 1 year later to ensure she remained cancer-free.

FLAP DESIGN

To design the flap, an adequate foundation is established by correcting volume deficits in the adjacent cheek, upper lip, nasal floor, sill, and columella. A healthy wound bed is created and all obstructing tissue is cleared from the nasal passage. A foil template of the resulting defect is made (Fig. 2). The ulnar neurovascular axis is marked. The template is placed over the ulnar forearm and Doppler imaging is used to identify septocutaneous perforators.

FLAP HARVEST AND INSET

Under tourniquet control, the radial-side flap incision is made. Suprafascial dissection continues to the ulnar border of the flexor digitorum superficialis. The ulnar neurovascular bundle is identified subfascially and septocutaneous perforators are visualized. The proximal incision is made and the ulnar artery dissected in retrograde fashion, and then ligated distally. The vascular pedicle is

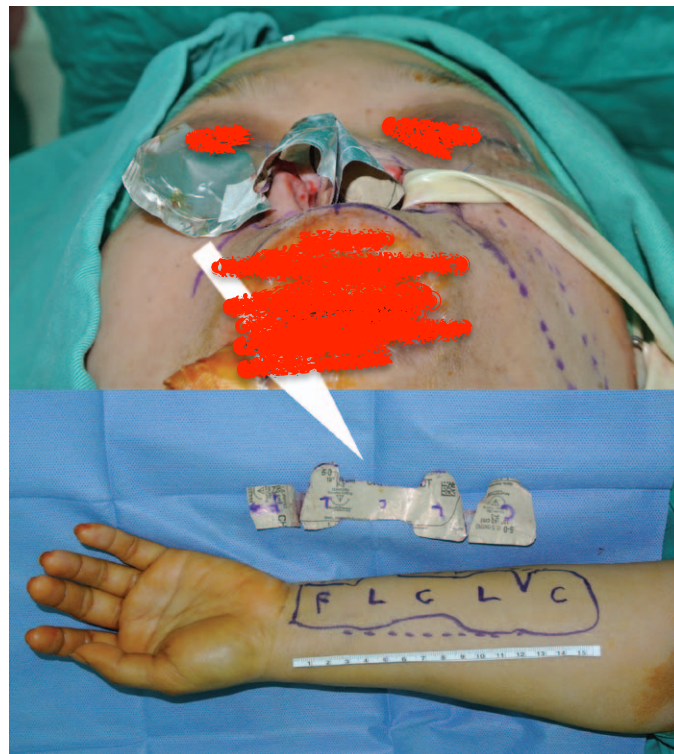

Fig. 2. A template is fashioned and a Penrose drain is used to facilitate pedicle transfer to the left facial vessels. Transposing this to the ulnar forearm, a 16-cm flap design emerges with five components: the covering flap (C) (proximal), vault lining (L) (proximal), columella (C) (distal), vault lining (L) (distal), and nasal floor (F).

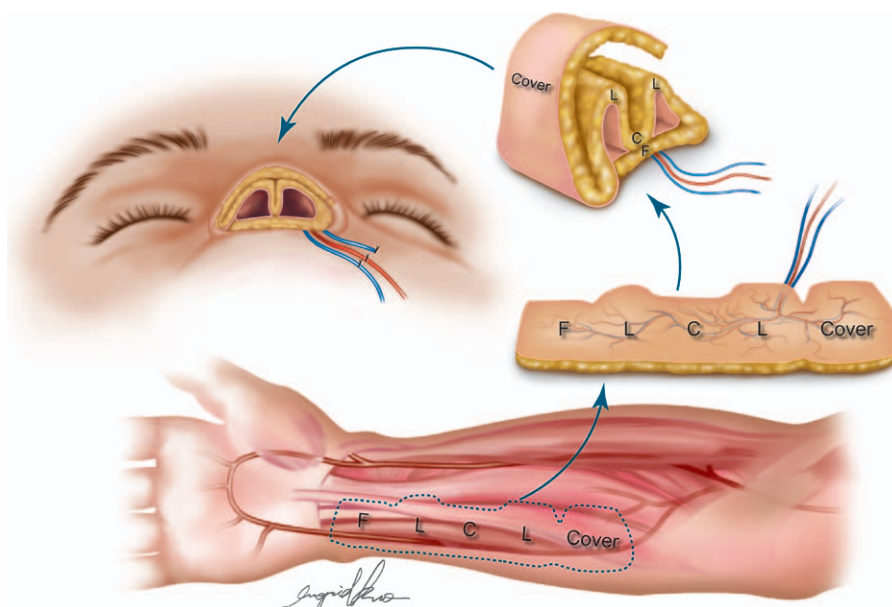


Fig. 3. Schematic for flap design (*below*), configuration (*above right and center, right*), and inset (*above, left*) in total nasal reconstruction.

freed from the ulnar nerve and the incision is completed along the ulnar side. The remaining flap is elevated suprafascially. The tourniquet is released to ensure adequate perfusion before dividing the pedicle. The wound is typically covered with skin graft.

Areas of the ulnar forearm flap for nasal floor, lining, and columella resurfacing are designated. The order is as seen in Figures 2 and 3: (proximal) skin cover, nasal lining, columella, nasal lining, and floor (distal). The floor is inset first and tubularized to make the inner lining of one nasal vault. The flap is folded to create a neoseptum and tubularized to create a second nasal passage. Free edges of caudal neoseptum are sewn together to make a columella. Remaining tissue is reflected to resurface the skin. Facial vessels are typically used as recipients (Table 1).

SUBSEQUENT STAGES

The nasal framework is constructed 4 to 6 weeks later and overbuilt to counter contractile forces and minor trauma. Autologous seventh rib is typically used. To prevent postoperative warping of the dorsal graft, a chimeric strut can be made by implanting a bony strip into the cartilage graft.⁶ Cartilages are secured with 5-0 nonabsorbable monofilament sutures. A paramedian forehead flap is designed to resurface the framework. In a final stage, the forehead flap pedicle is divided. Additional refinements are carried out months

later to create nasal grooves, enhance definition, and open the airway (Fig. 4).

DISCUSSION

Aesthetics and donor-site morbidity are critical considerations in modern reconstructive surgery. Pleasant aesthetic results and good function^{1,2} are enhanced with thoughtful planning.⁷ An often-overlooked consideration is donor-site appearance. Although material properties and reliability of the radial forearm flap are superior to most alternatives, the radial forearm bears hair,⁸ and the donor site may be stigmatic and difficult to conceal at mid supination.

We prefer the ulnar forearm flap because of its donor-site benefits and safety profile. The idea of teasing the vascular pedicle from the ulnar nerve may evoke concern, but Huang reported transient neurapraxia in only two of 50 ulnar forearm flaps harvested; Rodriguez et al. reported unaffected hand function and no long-term morbidity.^{9,10} In a series of 242 cases, Tan et al. corroborate the experience of Rodriguez et al. and Huang, supporting the ulnar forearm flap because of its improved donor-site characteristics.¹¹ The ulnar forearm is typically less hirsute than the radial forearm and confers superior aesthetic results.^{8,10,12–14}

Huang et al. described ulnar artery and vein diameters as 2.3 ± 0.6 mm and 1.7 ± 0.6 mm, respectively. The mean number of perforators was 4.3 ± 1.2 , and distalmost perforators were within 5 cm of the

Table 1. Patient Information

Case	Age/ Sex	Cause	Adjuvant Therapy	Extent of Defect	Previous Operation	No. of Operations				Additional Flaps Used	Lining, Flap Size (Random Component*) (cm)	Lining,	Framework	Reconstruction Period (mo)	Follow- Up (mo)	Complications
						Lining	FFNR	Revision	Sum							
1	52/M	SCC	RT	Total	FFNR	1	3	4	8	Forehead flap	12 × 4.5	V, C	CDOG, CS, BARG	16	44	Severe infection
2	76/F	SCC	—	Total	—	2	3	3	8	—	17 × 4 (4)	F, V, C	CDOG, CS, BARG	8	42	Partial flap loss
3	33/F	Infection	—	Total	—	2	3E	3	8	ALT	16 × 5 (3.5)	F, V, C	CDOG, CS, BARG	15	22	—
4	31/M	Infection	—	Total	FFNR	1	3	3	7	—	15 × 4.5 (3)	F, V, C	CDOG, CS, BARG	11	32	—
5	32/F	Infection	—	Total	FFNR	1	3E	1	5	—	15 × 4.5	V, C	CDOG, CS, BARG	10	29	—
6	48/M	Trauma	—	Dorsum	—	1	3	1	5	—	11 × 4	V	CDOG	9	26	—
7	48/F	Lymphoma	RT, CT	Total	—	1	3	3	7	—	15 × 4 (3.5)	F, V, C	CDOG, CS, BARG	15	21	Infection
8	52/F	Congenital	—	Dorsum, columella, tip	FFNR	1	3	2	6	—	13 × 4.5	V, C	CDOG, CS, BARG	11	18	—
9	67/M	SCC	RT	Columella, tip	—	1	3	1	5	—	16.5 × 4.5 (3)	F, V, C	SG, CS, BARG	18	24	Infection
10	37/M	Trauma	—	Columella, tip	—	1	3	5	5	—	14 × 4	V, C	SG, CS, BARG	9	20	—

SCC, squamous cell carcinoma; M, male; F, female; RT, radiation therapy; CT, chemotherapy; FFNR, forehead flap nasal reconstruction; E, pre-tissue-expanded; SCC, squamous cell carcinoma; ALT, anterolateral thigh; V, vault; C, columella; F, floor; CDOG, chimeric dorsal onlay graft; CS, columellar strut; BARG, bilateral alar rim graft; SG, spreader graft; RT, radiation therapy; CT, chemotherapy.

*The length of random component part of the forearm ulnar flap.

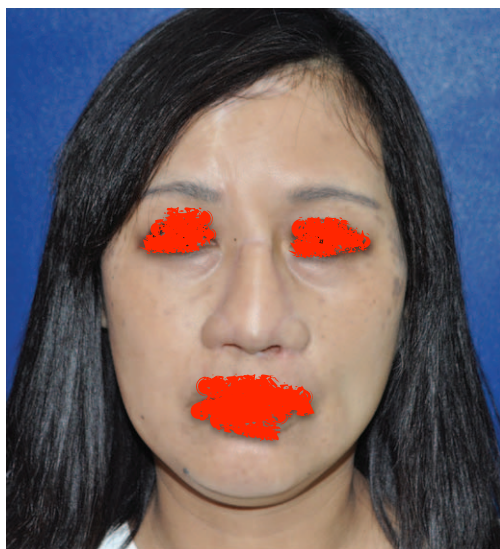

Fig. 4. Postoperative view, 24 months after ulnar forearm reconstruction with subsequent framework reconstruction, paramedian forehead flap coverage, and three refinement operations for improved airway patency and contour.

proximal wrist crease.¹² Perforators were larger than those arising from the radial artery, and each was capable of perfusing the flap individually.¹⁴ Accordingly, the ulnar forearm flap can be segmented into two or more independent flaps, each supplied by one or more perforators; this may be beneficial for coverage of topographically complex defects.

One disadvantage of the ulnar forearm flap is pedicle length, reported as 10 cm in one series,¹⁵ or 1 or 2 cm shorter than the radial forearm flap pedicle.⁸ Ten centimeters approaches the distance between the alar base and facial vessels at the mandibular angle. Centimeters count, but in our experience, the pedicle reached without tension in every case. Another foreseeable disadvantage of the folding method is pedicle kinking, especially near the columella. The series reported by Huang et al. identified sizable perforators 5 cm from the wrist crease; distal perforators are expected to provide perfusion even if a proximal perforator or perforators are compromised. It is understood that a single perforator is adequate to perfuse the flap, yet as many as seven were identified in the series reported by Huang et al.¹²

The folded lining flap technique is designed to be straightforward; placement of the columella in the center of a nearly symmetric flap minimizes guesswork. The ulnar forearm flap is amenable to folding and chimeric segmentation. Superior donor-site appearance can be expected. The covering flap can be used for salvage if complications occur. Suprafascial flap elevation offers a vascular

CODING PERSPECTIVE



The coding perspective provided by Dr. Raymund Janevicius is intended to provide coding guidance.

- 15757 Free skin flap with microvascular anastomosis
- 30999 Fashioning nasal soft-tissue framework (unlisted procedure code)
- 15100-51 Split-thickness skin graft to forearm donor site
- 21230-58 Graft; rib cartilage, autogenous, to face, chin, nose, or ear (includes obtaining graft)
- 15731-58 Forehead flap with preservation of vascular pedicle (e.g., axial pattern flap, paramedian forehead flap)
- 15630-58 Division and inset of forehead flap

- The free ulnar flap is reported with code 15757. The free flap code is global and includes:
 - Harvest of the free flap
 - Dissection of recipient vessels
 - Microvascular anastomosis of one artery and two veins
 - Inset of the flap
 - Direct closure of the donor site
 - Monitoring of the flap intraoperatively and postoperatively
- Closure of the donor site with a split-thickness skin graft is not included, and code 15100 is reported in addition to the free flap donor site.
- Free flap codes include straightforward inset but do not include involved procedures such as fashioning a nasal soft-tissue framework and neo-septum. There is no code for complete nasal reconstruction such as this, so an unlisted procedure code is used, 30999.
- Code 21230 describes the placement of a rib cartilage graft. The code includes both harvest and placement of the graft.
- The forehead flap is described with code 15731. The division and inset of the forehead flap is reported with code 15630.
- All procedures subsequent to the primary surgery require modifier 58 to indicate that they are staged procedures. Since they occur during the 90-day global postoperative period, they would be rejected without modifier 58.
- All nasal reconstructive procedures must be preauthorized *in writing* with the payer prior to surgery, especially when using an unlisted procedure code such as 30999.

wound bed promising dependable skin graft take. Aesthetic outcomes after ulnar forearm flap reconstruction are superior to radial forearm flap outcomes, largely because less hair growth occurs. The risk of ulnar nerve injury after ulnar forearm flap harvest is an important consideration, but thoughtful dissection nearly eliminates the risk of sensory and functional impairment. [See **Figure, Supplemental Digital Content 1**, which demonstrates a 76-year-old woman with full-thickness loss of the nasal floor, vault, and columella after squamous cell carcinoma tumor extirpation. (*Above, left*) Wound bed after scar resection, mobilization of surrounding tissue, and clearing the airways. (*Above, center*) Foil is used as a template, inset the way the flap would be inset. (*Below, left*) The 17-cm template is unfurled and centered about the ulnar arterial axis, with each component designated to nasal floor (F), vault and columella (L), and cover (C). (*Right*) The on-table result of lining reconstruction. Red rubber catheters stent the airways and a cadaveric homograft cartilage strut provides stability, <http://links.lww.com/PRS/B566>. See **Figure, Supplemental Digital Content 2**, which demonstrates preoperative and postoperative views at 41 months, <http://links.lww.com/PRS/B567>. See **Figure, Supplemental Digital Content 3**, which demonstrates postoperative donor-site view, 31 months after ulnar forearm harvesting, <http://links.lww.com/PRS/B568>.]

SUMMARY

The ulnar forearm flap is a safe and reliable donor in nasal reconstruction. We have used the ulnar forearm flap for nasal reconstruction in 10 patients, and all had satisfactory aesthetic and functional results. One of 10 patients suffered from partial flap necrosis and three had infection. In our experience, 6.4 operations (range, five to eight operations) over 11.1 months (range, 8 to 18 months) were needed to achieve good aesthetic and functional results.

Georgios Kolios, M.D., M.B.A.

Department of Plastic and Reconstructive Surgery
Chang Gung Memorial Hospital
5, Fu-Hsing Street, Kweishan,
Taoyuan 333, Taiwan
nosehsiao@gmail.com

PATIENT CONSENT

The patient provided written consent for the use of her images.

REFERENCES

1. Burget GC, Walton RL. Optimal use of microvascular free flaps, cartilage grafts, and a paramedian forehead flap for aesthetic reconstruction of the nose and adjacent facial units. *Plast Reconstr Surg*. 2007;120:1171–1207; discussion 1208.
2. Menick FJ, Salibian A. Microvascular repair of heminasal, subtotal, and total nasal defects with a folded radial forearm flap and a full-thickness forehead flap. *Plast Reconstr Surg*. 2011;127:637–651.
3. Walton RL, Burget GC, Beahm EK. Microsurgical reconstruction of the nasal lining. *Plast Reconstr Surg*. 2005;115:1813–1829.
4. Menick FJ. A 10-year experience in nasal reconstruction with the three-stage forehead flap. *Plast Reconstr Surg*. 2002;109:1839–1855; discussion 1856–1861.
5. Menick FJ. A new modified method for nasal lining: The Menick technique for folded lining. *J Surg Oncol*. 2006;94:509–514.
6. Hsiao YC, Abdelrahman M, Chang CS, et al. Chimeric autologous costal cartilage graft to prevent warping. *Plast Reconstr Surg*. 2014;133:768e–775e.
7. Murrell GL, Burget GC. Aesthetically precise templates for nasal reconstruction using a new material. *Plast Reconstr Surg*. 2003;112:1855–1861.
8. Sieg P, Bierwolf S. Ulnar versus radial forearm flap in head and neck reconstruction: An experimental and clinical study. *Head Neck* 2001;23:967–971.
9. Brown EN, Chaudhry A, Mithani SK, et al. Long-term vascular, motor, and sensory donor site outcomes after ulnar forearm flap harvest. *J Reconstr Microsurg*. 2014;30:115–120.
10. Rodriguez ED, Mithani SK, Bluebond-Langner R, Manson PN. Hand evaluation following ulnar forearm perforator flap harvest: A prospective study. *Plast Reconstr Surg*. 2007;120:1598–1601.
11. Tan ST, James DW, Moaveni Z. Donor site morbidity of free ulnar forearm flap. *Head Neck* 2012;34:1434–1439.
12. Huang JJ, Wu CW, Lam WL, et al. Anatomical basis and clinical application of the ulnar forearm free flap for head and neck reconstruction. *Laryngoscope* 2012;122:2670–2676.
13. Menick FJ. Discussion: Optimal use of microvascular free flaps, cartilage grafts, and a paramedian forehead flap for aesthetic reconstruction of the nose and adjacent facial units. *Plast Reconstr Surg*. 2007;120:1208–1216.
14. Wong CH, Lin JY, Wei FC. The bottom-up approach to the suprafascial harvest of the radial forearm flap. *Am J Surg*. 2008;196:e60–e64.
15. Mathy JA, Moaveni Z, Tan ST. Perforator anatomy of the ulnar forearm fasciocutaneous flap. *J Plast Reconstr Aesthet Surg*. 2012;65:1076–1082.